

A Comparative Study on the Superior, Supero-Temporal and the Temporal Incisions in Small Incision Cataract Surgeries for Post Operative Astigmatism

VAISHALI SATYAJEET PAWAR, D. K. SINDAL

ABSTRACT

Introduction: Cataract surgery is no more a blind rehabilitation surgery. With all the possible modalities of cataract surgery, we try to give a normal vision. But Surgically Induced Astigmatism (SIA) is one of the causes of a poor quality of vision. We have studied SIA in 3 different sites of incision in Manual Small Incision Cataract Surgery (SICS).

Purpose: To compare the amount of surgically induced astigmatism after the superior, supero-temporal and the temporal incisions in manual small incision cataract surgery.

Materials and methods: Three hundred patients were studied. The patients were randomly assigned to any of three groups. The three groups had 100 patients each. The patients in group A underwent manual SICS with a superior incision, the patients in group B underwent manual SICS with a supero-temporal incision and the patients in group C underwent manual SICS with a temporal incision. The patients were examined on the postoperative days 1,7,21 and 45. The uncorrected and the best-corrected

visual acuity was recorded and a slit-lamp examination and auto-refractometer and keratometry examinations were also done.

Statistics: All the calculations were performed by using the Surgically-Induced Astigmatism (SIA) calculator version 2.1, a free software program. The one way ANOVA test was also applied.

Results: The mean SIA in group A was found to be 1.572 ± 0.651 , in group B, it was 0.532 ± 0.317 and in group C, it was 0.435 ± 0.338 . The F score which was applied was found to be 186.44. This value was more than the standard value.

The p-value accordingly was < 0.001 , which was highly significant.

Conclusion: SICS which is done with a temporal and a supero-temporal approach provides a better quality of vision due to a significantly less SIA than the superior approach.

Key Words: Astigmatism, Small incision cataract surgery, Superior incision, Temporal incision, Supero-temporal incision, Surgically induced astigmatism (SIA)

INTRODUCTION

The cataract is defined as an opacity in the lens capsule or its substance. It is the commonest cause of treatable blindness. The mainstay of the management of cataract is surgery. Cataract surgery is no more a blind rehabilitation surgery. But it gives absolutely a normal vision. Today's trend is manual Small Incision Cataract Surgery (SICS) and Phacoemulsification (Phaco) with posterior chamber intraocular lens implantation. Phaco is the most favoured method in the industrialized countries. In the developing countries like India, manual SICS is the most favoured method, as the Phaco machinery is expensive and it requires maintenance. Also, there is a steep learning curve [1]. The main aim of the cataract surgery is to provide a good vision quantitatively as well as qualitatively and an early visual rehabilitation.

Astigmatism means "without a point". Miller Stephen J defined astigmatism as a condition of refraction in which a point of light cannot be made to produce a punctate image upon the retina by a correcting spherical lens [2]. Astigmatism causes blurring of the images. Even with an appropriate spectacle correction, the meridional magnification can create distortion. In all types of cataract surgeries, the incisions which are made on the cornea

or the sclera give rise to scars, thus altering the curvature of the cornea. These scars cause corneal flattening along the meridian of the incision and steepening in the meridian 90° away [3]. This Surgically Induced Astigmatism (SIA) is one of the causes of the poor quality of vision post-operatively because of the blurring of images. SIA in turn, depends on the type, length and the position of the incision and also on the method of the wound closure [4]. Reddy et al., (2007) studied the comparison of astigmatism which was induced by superior and temporal sections in SICS in the Indian population, but their study had a smaller group of 64 patients only [5]. Gokhale et al., (2005) compared astigmatism which was induced by superior, supero-temporal and temporal incisions in manual SICS [6]. This study was hence undertaken to evaluate the results in a wider population group.

MATERIALS AND METHODS

This was a prospective, hospital based, randomized, controlled clinical study which was conducted between January 2010 - December 2011 with permission from the ethical committee of the institute. All the surgeries were conducted at the Department of Ophthalmology, Krishna Institute of Medical Sciences University,

KIMS, Karad, by 2 experienced surgeons. A total of 300 patients were selected. The patients were randomly assigned to any of three groups. The three groups had 100 patients each. The patients in group A underwent manual SICS with superior tunnel incisions, the patients in group B underwent manual SICS with supero-temporal tunnel incisions and the patients in group C underwent manual SICS with temporal tunnel incisions.

INCLUSION CRITERIA

The patients with nuclear and cortical cataracts which ranged from grade 1 to hyper mature cataracts. The posterior sub-capsular cataracts were selected.

EXCLUSION CRITERIA

The patients with associated glaucoma, traumatic cataract, complicated cataract, lenticular subluxation, poorly dilating pupils, previous intraocular or corneal surgeries or glaucoma surgeries, a doubtful zonular integrity due to pseudoexfoliation, corneal scarring or degeneration, macular degeneration and retinal pathology and those with intra-operative, post-operative complications were excluded.

METHODS

All the patients were pre-operatively assessed with visual acuity recording, slit-lamp bio-microscopy, tonometry and fundus examination by using a direct and indirect ophthalmoscope and 90 D or 78 D. Astigmatism was measured by using an autorefractometer and a keratometer if it was possible. The IOL power was calculated by contact A-scan biometry by using the SRK II formula. Pre-operative investigations like a complete haemogram, random blood sugar, routine urine and microscopy were done. Topical ofloxacin 0.3% eye drops were instilled four times a day, three days before the surgery. A pre-operative informed consent was taken from the patients. Topical tropicamide 0.8% with phenylephrine 5% and flurbiprofen (non-steroidal anti-inflammatory) eye drops were instilled every 15 minutes, 1 hour before the surgery. The patients were operated under peribulbar anaesthesia with 5 cc of a 3:2 mixture of injection Xylocaine 2% and Injection bupivacaine 0.5% with 150 I.U. of Hyaluronidase.

A conjunctival flap was made. A 6 mm frown shaped scleral incision which was 1.5 mm posterior to the limbus was made. In group A, the incision was made superiorly [Table/Fig-1], in group B it was made supero-temporally [Table/Fig-2] and in group C, it was made temporally [Table/Fig-3].

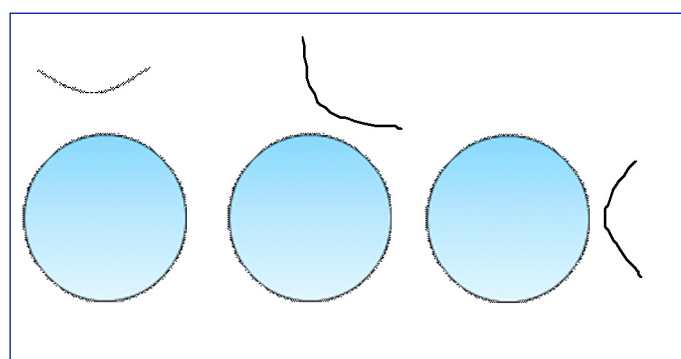
A three-plane sclero-corneal tunnel was created with a 15 No. blade and a crescent blade. Through a side port, the anterior chamber was filled with Trypan blue. After 30 seconds, the anterior chamber was washed and filled with a viscoelastic solution (Hydroxy Propyl Methyl Cellulose 2%). Capsulorrhexis was performed by using a 26 gauge needle. An entry into the anterior chamber was made with a sharp 3.2mm keratome to create a self sealing corneal valve and the internal opening was extended with the same keratome up to 7 mm, which was slightly larger than the external one. Hydro-dissection and delineation were performed. The upper pole of the nucleus was prolapsed out of the capsular bag. Through the scleral tunnel, the nucleus was delivered directly by visco-expression. The cortical matter was aspirated with simcoe two way irrigation and aspiration cannula. In the presence of a viscoelastic solution, a rigid posterior chamber 6x12.5 mm PMMA intraocular lens was implanted in the posterior chamber. The visco solution was removed

from the anterior chamber by irrigation with ringer lactate by using a simcoe cannula. A corneal stromal hydration was performed at the wound edges. A sub-conjunctival injection, Gentamicin 20 mg mixed with Dexamethasone 2mg was injected in the lower fornix. The eye was bandaged for 24 hours. Post-operatively, oral antibiotics (Tab.Ofloxacin 200 mg twice daily) and analgesics were given. The patients were examined on the post-operative days 1,7, 21 and 45. The uncorrected and the best corrected visual acuity were recorded; slit-lamp examination, fundus examination and autorefractometer and keratometry examinations were done. A topical antibiotic – steroid combination eye drop (Ofloxacin 0.3%- Dexamethasone 0.1%) was instilled every 2 hourly for the first 7 days in the operated eye and then in tapering doses over a period of 45 days. Proper eye care was advised to the patients to prevent eye infections, like hand washing, proper instillation of the eye drops and avoidance of coughing and lifting heavy weights. The patients were asked to come for regular follow ups.

All the calculations were performed by using the surgically induced astigmatism (SIA) calculator version 2.1, a free software program [7]. The Surgically Induced Astigmatism was calculated from the pre and the postoperative keratometric values, as was described by Holladay et al., [8]. The comparison between the groups was done by using InStat (a statistical software program) in steps like comparing the means and performing the ordinary ANOVA test and the assuming values were sampled from the Gaussian distribution.

RESULTS

A total of 300 eyes were operated on. There were 100 eyes in each group. The age distribution of the patients in the different groups was as has been shown in [Table/Fig-4]. The sex distribution of the patients in the different groups was as has been shown in [Table/Fig-5]. The mean SIA in group A was found to be 1.572 ± 0.651 , in group B, it was 0.532 ± 0.317 and in group C, it was 0.435 ± 0.338 [Table/Fig-6]. The F score which was applied was found to be 186.44. This value was more than the standard value.



[Table/Fig-1]: Superior, [Table/Fig-2]: Supero-temporal, [Table/Fig-3]: Temporal

Patients' age Age (years)	No of patients		
	Superior	Superior-temporal	Temporal
41-50	0	3	0
51-60	40	36	42
61-70	53	49	43
71-80	7	12	15
Total	100	100	100

[Table/Fig-4]: Age Distribution of Patients in different Groups.

Patients's	No of patients		
	Superior	Superior-temporal	Temporal
Male	45	46	62
Female	55	54	38
Total	100	100	100

[Table/Fig-5]: Sex Distribution of Patients in different Groups.

Incision location	Number of patients	Surgically induced astigmatism (SIA)
Superior	100	1.572 ± 0.651
Superior-temporal	100	0.532± 0.317
Temporal	100	0.435 ±0.338

[Table/Fig-6]: Surgically induced astigmatism (SIA)

Comparison	Mean Difference	q	p
Group A vs. Group B	1.040	22.52	***P<0.001
Group A vs. Group C	1.138	24.63	***P<0.001
Group B vs. Group C	0.0975	2.112	NS p>0.05

[Table/Fig-7]: Comparison between the groups

One way Analysis of Variance (ANOVA) with post tests showed a p value of < 0.0001, which was highly significant.

The mean of the variation among the groups was significantly greater than that which was expected by chance [Table/Fig-7].

The Bartlett's statistics was 67.490 and so, p was < 0.0001. This suggested that the difference between the standard deviations was extremely significant.

DISCUSSION

The sutureless manual Small Incision Cataract Surgery (SICS) is a good alternative to Phacoemulsification and it gives visual results which are equivalent to Phacoemulsification, at lower expenses.

But the rates of astigmatism are higher due to the larger sizes of the incisions. In order to achieve an excellent visual acuity, the effect of astigmatism on the postoperative vision has to minimize. Burgansky et al have reported an increase in astigmatism with an increase in the incision size [9]. A pre-existing astigmatism can be neutralized by changing the site of the incision.

When the incision is located superiorly, both the gravity and the blinking of eyelid tend to create a drag on the incision. These forces are neutralized better with temporally placed incisions because in such cases, the incision is parallel to the vector of the forces [10]. But a superior incision is easy to learn and the upper eyelid covers the incision and so the wound is protected and the foreign body sensation is less. The temporal location is the farthest from the visual axis and any flattening which is caused by the wound is less likely to affect the corneal curvature at the visual axis. A temporal incision is advantageous because it can be made easily in deep sockets and small eyes. Also, the superior site is still there if a trabeculectomy surgery has to be done for glaucoma in the future. But it is difficult to learn and the upper lid does not cover the incision and so the foreign body sensation due to the exposure is more and it is exposed to infection.

The supero-temporal location has the advantages of both the

locations. The supero-temporal incision is free from the effect of gravity and eyelid pressure and it tends to induce less astigmatism. The astigmatism which was induced in manual SICS which was done with superior, supero-temporal and temporal scleral tunnel incisions was compared. This study found that the induced astigmatism was lower in the temporal and supero-temporal groups as compared to that in the superior group. The astigmatism in the supero-temporal and the temporal groups was comparable.

In the study of Gokhale et al., (2005), the SIA in the superior group was 1.28D, it was 0.2D in the superotemporal group and it was 0.37D in the temporal group. Our study also showed similar results, with the superior group having an SIA of 1.57D, an SIA of 0.53D in the supero-temporal group and that of 0.435D in the temporal group.

CONCLUSION

SICS with the superior-temporal and the temporal approaches provides a better quality of vision due to the significantly less SIA than the superior approach. But the supero-temporal incision has the advantages of both the locations and so it is better than the temporal incision.

REFERENCES

- [1] Minnassian DC, Rosen P, Dart JK, Reidy A, Desai P, Sindhu M. Extra capsular cataract extraction compared with small incision surgery by phacoemulsification: a randomized trial. *Br J Ophthalmol* 2001; Jul; 85(7): 822-29.
- [2] Miller SJ, Parson's Diseases of Eye. Edinburgh: Butterworth Hienmann International Edition. 18th edition 1990; 63-69.
- [3] Merriam JC, Zheng L, Merriam JE, Zaider M, Lindstrom B. The effect of incisions for cataract on corneal curvature. *Ophthalmology*. 2003 Sep; 110(9): 1807-13.
- [4] Koch PS. The structural analysis of cataract incision construction. *J Cataract Refract Surg* 1991; 17(suppl): 661-67.
- [5] Reddy B, Raj A, Singh VP. The sites of incision and corneal astigmatism in conventional SICS versus phacoemulsification. *Ann Ophthalmol (Skokie)* 2007; 39(3):209-16.
- [6] Gokhale NS, Sawhney S. Reduction in the astigmatism in manual small incision cataract surgery through change of incision site. *Indian J Ophthalmol* 2005; 53(3):201-03.
- [7] Sawhney S, Aggarwal A. The SIA calculator Version 2.1 –Calculating Surgically Induced Astigmatism using MS Excel. [Internet]. [Cited 2012 May 10]. Available from:http://www.insighteyeclinic.in/articles/SIA_Calc_2-1_Article.pdf.
- [8] Holladay JT, Dudeja DR, Koch DD. Evaluating and reporting astigmatism for individual and aggregate data. *J Cataract Refract Surg* 1998;24:57-65.
- [9] Burgansky Z, Isakov I, Avizemer H, Bartov E. Minimal astigmatism after sutureless, planned, extracapsular cataract extraction. *J Cataract Refract Surg* 2002; 28:499-503.
- [10] Merriam JC, Zheng L, Urbanowicz J, Zaider M. Change on the horizontal and vertical meridians of the cornea after cataract surgery. *Trans Am Ophthalmol Soc*. 2001;99:187-95.

AUTHOR(S):

1. Dr. Vaishali Satyajeet Pawar
2. Dr. D. K. Sindal

PARTICULARS OF CONTRIBUTORS:

1. Senior Resident , Department of Ophthalmology,
2. Professor & Head, Department of Ophthalmology,
Krishna Institute of Medical Sciences ,Karad,
Maharashtra 415110, India.

NAME, ADDRESS, E-MAIL ID OF THE CORRESPONDING AUTHOR:

Dr. Vaishali Satyajeet Pawar,
Senior Resident, Department of Ophthalmology,
Krishna Institute of Medical Sciences ,Karad,
Maharashtra, 415110, India.
Phone: 91-9423867394
E-mail: drvspawar269@gmail.com

FINANCIAL OR OTHER COMPETING INTERESTS:

None.

Date of Submission: **Jun 11, 2012**
Date of Peer Review: **Aug 12, 2012**
Date of Acceptance: **Aug 30, 2012**
Date of Publishing: **Sep 30, 2012**